

Congenital venous anomaly associated with capillary telangiectasia, a rare finding: report of two cases

Anomalía del desarrollo venoso asociado a telangiectasia capilar un hallazgo infrecuente: reporte de 2 casos

Leonardo Andrés Chacón Zambrano MD.¹, Carlos Alberto Lindado Pacheco MD.², Lady Carolina Delgado Salazar MD.³, Andrés Felipe González Arias MD.¹, Daniel Sebastián Contento Meléndez MD.⁴

¹ Neurosurgeon, Universidad Militar Nueva Granada, Hospital Militar Central. Bogotá, Colombia.

² Neurosurgery Resident, Pontificia Universidad Javeriana, Hospital Universitario San Ignacio. Bogotá, Colombia.

³ Medical Doctor, Universidad Autónoma de Bucaramanga.

⁴ Medical Doctor, Universidad Militar Nueva Granada.

Rev. Chil. Neurocirugía 45: 250-254, 2019

Abstract

Cerebrovascular malformations are rare pathologies in general population (1%), which are diagnosed by neurological symptoms produced by alteration on the dynamics of blood flow, or as incidental findings during CT Scan or Magnetic resonance with contrast agent studies. These lesions have been classified in four types: Anomalies on venous development, capillary telangiectasia, arteriovenous malformations and cavernous angioma. Nevertheless, it has not been possible to conclude if there are different entities or a same disease with different stages, since in some cases there is possible to identify more than one kind of lesion in the same patient, which is known as mixed vascular malformation, making a challenging situation for the medical treatment. The objective of this paper is to expose two cases of patients with mixed vascular malformations, it is the association between a venous development anomaly and capillary telangiectasia, in a supratentorial and in posterior fossa location, as an incidental finding during a magnetic resonance with contrast agent. We share these cases given the infrequency of their report in literature, which surely will allow to complement the knowledge about the natural history and etiology of cerebrovascular malformations, understanding better the pathology and giving a better treatment to the patients.

Key words: Central nervous system vascular malformations, brain capillary telangiectasia, brain vascular malformation, cerebral venous angioma, incidental.

Resumen

Las malformaciones cerebrovasculares son lesiones infrecuentes en la población general (1%), siendo diagnosticadas por síntomas neurológicos secundarios a la alteración de la dinámica del flujo sanguíneo o como hallazgos incidentales durante estudios por tomografía o resonancia magnética con medio de contraste. Se han clasificado comúnmente en cuatro tipos: Anomalías del desarrollo venoso, telangiectasias capilares, malformaciones arteriovenosas y angiomas cavernosos. Sin embargo aún no se ha podido llegar a concluir si se trata de entidades diferentes o a una misma entidad con diversas etapas evolutivas, ya que se presentan casos en donde es posible identificar más de una lesión en un mismo paciente, a lo que se conoce como malformaciones vasculares mixtas, presentando de esta manera un reto para el manejo médico cuando así sucede. El objetivo de este artículo es exponer dos casos de pacientes con malformaciones vasculares mixtas, se trata de la asociación infrecuente de una anomalía del desarrollo venoso y una telangiectasia capilar, de ubicación supratentorial y en fosa posterior, hallados de forma incidental durante un estudio de resonancia magnética con medio de contraste. Compartimos estos casos dado lo infrecuente de sus reportes en la literatura, lo que seguramente permitirá a futuro complementar el conocimiento con respecto a la historia natural y etiología de las malformaciones cerebrovasculares, repercutiendo esto en un mejor entendimiento de la patología y por consecuencia del manejo a nuestros pacientes.

Palabras clave: Malformaciones vasculares del sistema nervioso central, telangiectasia capilar cerebral, malformación vascular cerebral, angioma venoso cerebral, incidental.

Introduction

Cerebral vascular malformations represent a heterogeneous group of pathologies that has very different history and clinical implications. They are present in 1% of the population, and many of them won't need any kind of treatment due to its benign course¹. The modern concept of cerebral vascular malformation started with the observations made by Harvey Cushing and Walter Dandy², parallel to the development of neurological diagnostic techniques that allowed the identification of different kind of malformation such as the angiographically negative, leading to the understanding of the cavernous malformation as a different entity among the spectrum of cerebral vascular malformations³. Actual nomenclature for this malformations are based on the histological descriptions performed by Russell and Rubinstein, describing four types: arteriovenous malformations (AVM), cavernous angiomas (CA), capillary telangiectasia (CT) and venous angioma also known as venous development anomalies (VDA)^{1,2}, clinically, radiologically and pathologically this lesions are presented as different entities, nevertheless the coexistence of two or more lesions in the same patient have been described in previous publications, bringing the possibility that this malformations are the spectrum of an only disease with a unique pathogenesis^{1,4}. The most frequent and known association ins cerebral vascular malformations is between cavernous angiomas and venous angiomas, nevertheless the coexistence between venous angiomas and capillary telangiectasia is less frequent, it has been described only in six times according to the literature⁵⁻¹⁰, which has captured our attention in order to report the two cases received at a hospital in Bogotá, Colombia, that are described in this paper.

Case report

Case 1

A 49 years old female patient with medical history of migraine and ductal adenocarcinoma on right breast, which received surgical and pharmacological treatment, and free of the disease, she arrives to neurosurgery department referring headache episodes with no other neurological symptoms. A Magnetic resonance image was taken,

simple and with contrast agent (Figure 1), which put in evidence an isointense signal in thalamus, posterior arm of the internal capsule, and posterior part of putamen, in T1/T2 and hyperintense in FLAIR (Fluid Attenuated Inversion Recovery) projection, with high capitation of contrast agent, elated to a venous development anomaly in the right basal ganglia region, with some capillary highlight zones, suggesting capillary telangiectasia, with no other findings.

Case 2

A 31 years old male patient, with medical history of squamous cell carcinoma con right maxillary sinus, who received surgical treatment and in postoperative control claims he is having headache, a magnetic resonance image was taken, simple and with contrast agent (Figure 2), which reveal postoperative changes of right maxillary antrostomy, not showing any mass in skull base or nasal fos-

sa, additionally there was a lesion in the inferior aspect of the protuberance that captured contras agent, with a central blood vase, measured 8.9*10.6*9.9 mm, compatible with capillary telangiectasia associated with a venous development anomaly.

Discussion

The association of different cerebral vascular malformations in the same patient has been described in the literature, giving attention to the association between cavernous malformations and venous development anomalies, speculating about a causal relation between these lesions¹¹.

The physiopathology of cerebral vascular malformations is not clearly understood yet and it is not known if these malformations represent the spectrum of one disease with a unique pathogen-

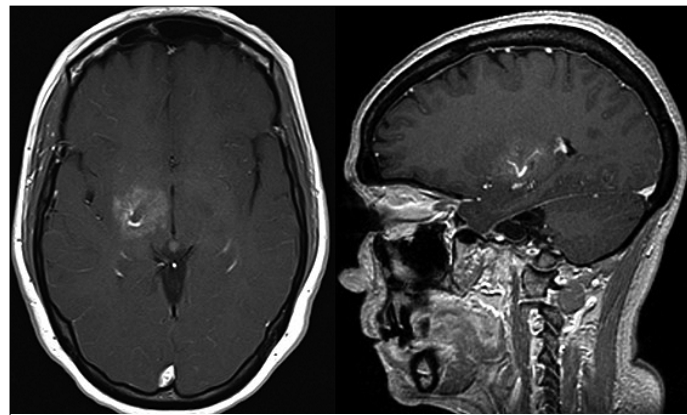


Figure 1. Magnetic Resonance image, in T1 sequence with contrast agent in axial and sagittal view. there is a "brush" pattern with a central vein in the right basal ganglia.

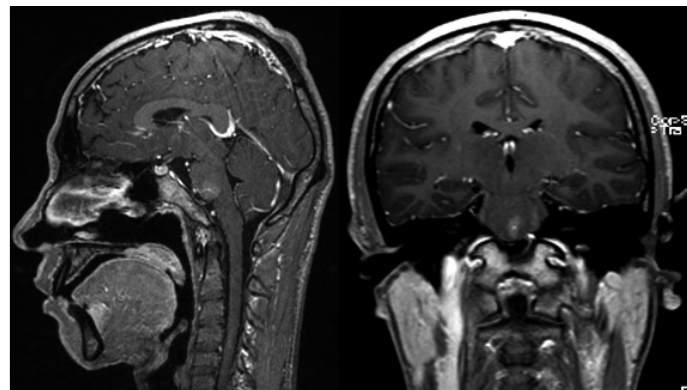


Figure 2. Magnetic Resonance image, in T1 sequence with contrast agent in axial and sagittal view. there is a "brush" pattern with a central vein in the anterior and inferior protuberance.

esis, or if their pathogenesis is the result of the different vascular subtypes separately⁷.

It is believed that most of vascular malformations have a congenital origin, in the case of venous malformations is from an alteration in the development during the 12th week of embryogenesis and in the case of capillary telangiectasia its due to a failure in capillary involution. In contrast with this, some authors accept that all the cerebral vascular malformation can be acquired or develop during extrauterine life, thanks to a reactive angiogenesis caused by a hemodynamic perturbation o capillary fragility^{1,7,9}.

Capillary telangiectasia

Capillary telangiectasia is a vascular malformation made by capillary which walls are thin, dilated, and lack of smooth muscle or elastic fibers, existing within a normal parenchyma, with no areas of gliosis or hemosiderin deposits nearby^{8,12,13}.

There is controversy about the pathogenesis of the capillary telangiectasia. Some authors believe that these are congenital lesions, while others claim that the association with other vascular malformations and the age of diagnosis suggest an acquire etiology. Rigamonti and colleagues consider the hypothesis that cavernous angiomas and capillary telangiectasia have similar origins but are in a different site of the spectrum¹². Even though multiple similarities between cavernous angiomas and capillary telangiectasia are considered, there are also multiple finding that show the difference between them, such as the presence or absence of cerebral parenchyma surrounding the vascular vessels, characteristics of the adjacent hemosiderin, bleeding and mass effect, among others^{12,13}.

Capillary telangiectasia is commonly identified as an incidental finding during an autopsy or as a radiological image during a magnetic resonance, are relatively frequent and comprise 4 - 12% of all vascular malformations¹⁴. Even though the can develop in any part of the brain, the most frequent location is the protuberance and represent the most frequent vascular malformation found as an incidental finding in autopsies in this location (0,1 - 0,2%)^{8,12,15}.

Clinical presentation is often silent, and it is more frequent to find the in an incidental way. Symptomatic cases present headache, nausea, ischemia and

occasionally hemorrhage^{8,12,14}. Sayama and collaborators found that 28.6% of capillary telangiectasia larger than 1 cm where symptomatic, while the ones lesser than where not¹⁴.

The diagnosis is made with magnetic resonance image, being necessary the use of contrast agent, Images potentiated in T1 may not reveal any signal change, T2 imagen can also be normal, even though in some cases an increase in signal intensity may be seen due to the paramagnetic effect provoked by deoxyhemoglobin, this characteristic gets more highlighted on sequences that increase magnetic susceptibility. Images taken in T1 after contrast agent is applied, show a characteristic capitation in a pointed or "brush" pattern. CT Scan studies are often normal, and any angiographic study is not indicated because characteristically these lesions are not seen on these techniques; this is why they are angiographically hidden¹⁶. Given its benign course and the small bleeding risk, conservative management is preferred^{8,15,17,18}.

Venous development anomaly

Consist on vascular dilations of multiple vessel that converge on a parenchymal principal dilated vessel, with a radial configuration made up of medullar veins separated by normal cerebral parenchyma^{8,12,17}. In a histological view the wall of these veins is thick and hyalinized, and usually lack of elastic tissue and smooth muscle, despite the variation of venous development anomalies drain normal tissue¹². In the past these lesions where known as venous angiomas but nomenclature change, showing its benign natural history¹⁷.

In general, it is accepted that venous development anomalies are formed during intrauterine life, but there is not a consensus about the mechanism that leads to its formation¹⁹. Saito and Kobayshi consider that during intrauterine life an ischemic event occurs during formation of the medullar veins leading to a collateral venous drainage¹².

Venous development anomalies are the most frequent cerebral vascular malformation found and reported as incidental findings in CT Scan and Magnetic resonance studies¹⁹⁻²². Its prevalence is 2,5 - 9% in magnetic resonance images with contrast agent²³, and constitute approximately 60% of all cerebral vascular malformations^{12,19,20-23}. Typically, they are located on the union between

the superficial and deep venous system, more frequent locations include: next to the frontal horn of the lateral ventricle (40%), parietal (36%), cerebellum (22%) and only 2% on the protuberance. In 19% of the patients it has been described a second malformation, mostly cavernous^{8,9,23}.

It has been proposed that Venous development anomaly represent an early stage among the spectrum of the development of cavernous malformations and other mixed vascular malformations and it is proposed an increase of venous pressure as a pathogenic mechanism^{8,10}.

Most cases of venous development malformations have a benign course with a low morbidity and mortality and are mostly incidental findings. The most frequent symptoms are headache, hemorrhage, venous thrombosis and seizures¹²⁻¹⁹.

Based on image finding and clinical symptoms Pereira and collaborators identified two principal pathogenic mechanisms for venous development anomalies, one is a mechanic mechanism present on 20% of the cases, which generates symptoms when any component of the malformation produce a compressive effect over near neurovascular tissue. Another mechanism is related to the blood flow, in which an imbalance between blood entrance and exit to the anomaly which occurs in 71% of the cases, that can be classified in those related a high blood flow (related to the drainage of the malformation), low blood flow (due to anatomic causes such as stenosis or clots in the vessels of the venous development anomaly) or due to functional causes, like in cases of arterial overload from a distant high flow leak^{19,20}.

Annual rate of symptomatic hemorrhage due to a venous development anomaly is approximately 0.22 - 0.68%, nevertheless in 18 - 40% of this kind of malformation are associated with one or more cavernous angiomas, which has a higher risk of bleeding, in these cases the treatment is focused on the cavernous angioma rather than in the venous development anomaly¹⁹.

The gold standard of diagnosis on these anomalies is cerebral angiography, but the magnetic resonance shows medullar veins, converging to a trans cerebral dilated vein with a characteristic "jellyfish head" pattern in potentiated sequences in T1 image^{8,19,21,22}.

In most cases of venous development anomaly treatment is conservative, keeping surgical management for patients with hemorrhage, in which case complementary studies are indicated to discard the coexistence of other cerebral vascular malformations, given the fact that the coexistence with other malformations the focus of the treatment becomes the companion vascular malformation, rather than the venous development anomaly. Performing a surgical obliteration of the venous anomaly may lead to venous thrombosis, venous congestion and hemorrhagic strokes, this is why it is important to preserve the venous anomaly and its collector vessels during the surgical treatment of its adjacent lesion^{8,17,19,21,24}.

Capillary telangiectasia a venous development anomaly

Using PUBMED database, using MESH terms “Vascular Malformations” AND “Central Nervous System Vascular Malformations”, it was performed a research of the literature reporting the coexistence of capillary telangiectasia and venous development anomaly, us-

ing as research limits papers written in English and report in human cases. There were 9 case report fulfilling the criteria^{5,11,25,26}, 6 described cases with capillary telangiectasia and venous anomaly, and 3 reporting coexistence of capillary telangiectasia, venous anomaly, and cavernous angioma. The characteristics of these articles are described in Table 1.

In the reported series there were 6 cases reporting the coexistence of only capillary telangiectasia an venous development anomaly, all of the where female patients, medium age of 34 years (ages from 24 - 45), in one of the cases, the age of the patient was not reported, the lesions were located in posterior fossa in 4 cases (2 on the protuberance, 1 on cerebellum and 1 on protuberance an medulla) and 2 cases had supratentorial locations (1 case in the right frontal corona radiata and 1 on the basal ganglia). Among the clinical manifestation 4 of the cases were symptomatic, 1 case showed up as an incidental finding and other had no information about symptoms. On the other side the series reporting cases of ve-

nous anomaly, capillary telangiectasia and cavernous angioma were 3, with 8 cases in total, 5 of them were female patients and 3 of them male patients, medium age was 37 years (ages from 14 - 81 years), in 7 cases the location was posterior fossa (protuberance and cerebella peduncles), in one case lesion were reported in thalamus and all cases were symptomatic.

Relating our cases to the reported cases on literature, we noticed that the age at diagnosis in both of our cases it's within the range of ages reported in literature. Distribution by sex y equivalent in our series, even though in the literature female sex predominates. Location of the lesions in our patients were in relation with the basal ganglia and in the other case in the protuberance; with the described information it can be said that the most frequent location for concomitant lesions of capillary telangiectasia and venous anomaly, as well as for those two coexisting with cavernous angioma, is the posterior fossa an exceptionally they are located in a supratentorial region, highlighting in this cases the location near the basal

Table 1.
Reviewed cases of the association of venous development anomaly and Capillary Telangiectasia

Case report	Age	Gender	Anomaly	Location	Symptoms
Clatterbuck, R. et al. 2001 (26)	52	Female	CA + CT + VDA	Protuberance	Confusion, fotofobia, neck pain, disfagia
Pozzati E. et al. 2007 (11)	14	Male	CA + CT + VDA	Protuberance + Cerebellar peduncle	Headache, walk perturbation
	43	Male	CA + CT + VDA	Protuberance	Headache, diplopia, walk alteration
	81	Female	CA + CT + VDA	Protuberance	Headache, Facial palsy
	29	Female	CA + CT + VDA	Protuberance	Dismetry, facial palsy
	35	Female	CA + CT + VDA	Protuberance	Diplopia
	21	Male	CA + CT + VDA	Protuberance	Headache vertigo, walk perturbation
Abla A. et al. 2008 (25)	23	Female	CA + CT + VDA	Talamous	Headache, memory issues, hemiparesia
McCormick P. et al. 1993 (10)	24	Female	CT + VDA	Left cerebellum	Headache, vertigo, coordination anomaly
Van Roost D. et al. 1997 (9)	45	Female	CT + VDA	Right frontal Corona radiata	headache
Ozcan H. et al. 2011 (6)	32	Female	CT + VDA	Protuberance + medulla	Nistagmus, diplopia, ataxia
Sarac H. et al. 2011 (7)	42	Female	CT + VDA	Protuberance	Facial palsy
De Gennaro et al. 2012 (5)	Not said	Female	CT + VDA	Basal ganglia	ND
Arcalís N. et al. 2013 (8)	27	Female	CT + VDA	Protuberance	Incidental

ganglia. Apart from what was found on literature, the two exposed cases where incidental finding on imaging studies, while in most case reports patients have had symptoms.

Conclusion

The association of a venous develop-

ment anomaly and a cerebral capillary telangiectasia in the same patient is often an infrequent finding, usually identified in symptomatic patients, or incidentally on magnetic resonance images with contrast agent. The natural course of this mixed vascular malformation is not well known given the low frequency of reports and following, which makes complicate to identify whether its ori-

gin is congenital or acquired. Treatment is often an expecting one with image follow up, and a surgical treatment is only proposed in patients with hemorrhage, in which case it is indicated to preserve de drainage pater towards the venous development anomaly.

Recibido: 10 de febrero de 2019

Aceptado: 15 de marzo de 2019

References

- McCormick W. The pathology of vascular "arteriovenous" malformations. *J Neurosurg.* 1966; 24(4): 807-816.
- Gault J, Sarin H, Awadallah N, Shenkar R, Awad I. Pathobiology of human cerebrovascular malformations: basic mechanisms and clinical relevance. *Neurosurgery.* 2004; 55(1): 1-16.
- Robinson J, Awad I, Masaryk T, Estes M. Pathological heterogeneity of angiographically occult vascular malformations of the brain. *Neurosurgery.* 1993; 33: 547-555.
- Dillon W. Cryptic vascular malformations: controversies in terminology, diagnosis, pathophysiology, and treatment. *AJNR Am J Neuroradiol.* 1997; 18(10): 1839-1846.
- De Gennaro A, Manzo G, Serino A, Fenza G, Manto A. Large capillary telangiectasia and developmental venous anomaly of the Basal Ganglia: an unusual finding. *Neuroradiol J.* 2012; 25(6): 744-749.
- Ozcan H, Avcu S, De Bleecker J, Lemmerling M. MRI findings in giant pontine capillary telangiectasis associated with a developmental venous anomaly. *JBR-BTR.* 2011; 94(5): 293-294.
- Sarac H, Telarović S, Markeljević J, Perić B, Pavliša G, Rados M. Symptomatic capillary telangiectasia of the pons and intracerebral developmental venous anomaly - A rare association. *Coll Antropol.* 2011; 35: 333-338.
- Arcalís N, Medrano S, Cuadrado M, García D. [Capillary telangiectasia and developmental venous anomaly: a rare association]. *Radiología.* 2013; 55(4): 353-356.
- Van Roost D, Kristof R, Wolf H, Keller E. Intracerebral capillary telangiectasia and venous malformation: a rare association. *Surg Neurol.* 1997; 48(2): 175-183.
- McCormick P, Spetzler R, Johnson P, Drayer B. Cerebellar hemorrhage associated with capillary telangiectasia and venous angioma: a case report. *Surg Neurol.* 1993; 39(6): 451-457.
- Pozzati E, Marliani A, Zucchelli M, Foschini M, Dall'Olio M, Lanzino G. The neurovascular triad: mixed cavernous, capillary, and venous malformations of the brainstem. *J Neurosurg.* 2007; 107(6): 1113-1119.
- Flemming K, Brown R. *The Natural History Of Intracranial Malformations.* In Winn H, editor. *Youmans Neurological Surgery. Sixth Edition ed.* Philadelphia: Elsevier Saunders; 2011. p. 4030-4032.
- Gross B, Puri A, Popp A, Du R. Cerebral capillary telangiectasias: a meta-analysis and review of the literature. *Neurosurg Rev.* 2013; 36(2): 187-193.
- Sayama C, Osborn A, Chin S, Couldwell W. Capillary telangiectasias: clinical, radiographic, and histopathological features. *Clinical article. J Neurosurg.* 2010; 113(4): 709-714.
- Barr R, Dillon W, Wilson C. Slow-flow vascular malformations of the pons: capillary telangiectasias? *AJNR Am J Neuroradiol.* 1996; 17(1): 71-78.
- Lee R, Becher M, Benson M, Rigamonti D. Brain capillary telangiectasia: MR imaging appearance and clinicohistopathologic findings. *Radiology.* 1997; 205(3): 797-805.
- Nussbaum E. Vascular malformations of the brain. *Minn Med.* 2013; 96(5): 40-43.
- Chalouhi N, Dumont A, Randazzo C, Tjoumakaris S, Gonzalez L, Rosenwasser R, et al. Management of incidentally discovered intracranial vascular abnormalities. *Neurosurg Focus.* 2011; 31(6): E1.
- Cohen J, Boitsova S, Moscovici S, Itshayek E. Concepts and controversies in the management of cerebral developmental venous anomalies. *Isr Med Assoc J.* 2010; 12(11): 703-706.
- Pereira V, Geibprasert S, Krings T, Aurboonyawat T, Ozanne A, Toulgoat F, et al. Pathomechanisms of symptomatic developmental venous anomalies. *Stroke.* 2008; 39: 3201-3215.
- Wilms G, Marchal G, Van Hecke P, Van Fraeyenhoven L, Decrop E, Baert A. Cerebral venous angiomas. MR imaging at 1.5 tesla. *Neuroradiology.* 1990; 32: 81-85.
- Zouaoui A, Maillard J, Ganthier V, Chedid G, Dangeard S. Modern imaging in cerebral vein angioma. *J Neuroradiol.* 1995; 22: 86-102.
- Lee C, Pennington M, Kenney C. MR evaluation of developmental venous anomalies: medullary venous anatomy of venous angiomas. *AJNR Am J Neuroradiol.* 1996; 17(1): 61-70.
- Gülşen S, Altınörs N, Atalay B, Benli S, Kaya Y. Treatment differences in cases with venous angioma. *Turk Neurosurg.* 2007; 17(1): 40-44.
- Abla A, Wait S, Uschold T, Lekovic G, Spetzler R. Developmental venous anomaly, cavernous malformation, and capillary telangiectasia: spectrum of a single disease. *Acta Neurochir (Wien).* 2008; 150(5): 487-489.
- Clatterbuck R, Elmací I, Rigamonti D. The juxtaposition of a capillary telangiectasia, cavernous malformation, and developmental venous anomaly in the brainstem of a single patient: case report. *Neurosurgery.* 2001; 49(5): 1246-1250.

Correspondence:

Daniel Contento

Neurosurgery department, Hospital Militar Central, Tv. 3 N° 40-00, Bogotá, D.C., Colombia,

Tel: 3486868 ext: 5285

Daniel.contento.melendez@gmail.com