

Giant pediatric meningioma: Case report and review of literature

Meningioma gigante en paciente pediátrico: reporte de caso y revisión de la literatura

César J. Chong MD.¹, Xavier Wong-Achi MD.², Jenniffer S. Plaza MD.², Gabriela Egas MD.³

¹ Department of Neurosurgery, National Oncologic Institute "Dr. Juan Tanca Marengo" ION-SOLCA. Guayaquil, Ecuador.

² Department of General Surgery, National Oncologic Institute "Dr. Juan Tanca Marengo" ION-SOLCA. Guayaquil, Ecuador.

³ Division of Critical Care Medicine, "Dr Teodoro Maldonado Carbo" regional hospital. Guayaquil, Ecuador.

Rev. Chil. Neurocirugía 45: 246-249, 2019

Abstract

Meningiomas arise from the meningeal coverings of the central nervous system. Pediatric meningiomas are infrequent tumors accounting for 0.5% to 5% of central nervous system tumors in the pediatric age group, being the most common nonglial primary brain tumor. There is no confirmed evidence for the pathogenesis of pediatric meningiomas. Usually they are located in the supra or infratentorial convexity, intraventricular and skull base. The clinical presentation of pediatric meningiomas is nonspecific, varies according to its location and size. Meningiomas subtypes in childhood are mainly WHO grade I meningothelial (32%). The treatment of choice is a complete tumor resection (Simpson I) to prevent recurrence and improve prognosis. We present a case of a 9-year-old female child with a large frontal meningioma, a prevalence report in our institution as well as a review of the current literature of this pathology.

Key words: Pediatric meningioma, review, epidemiology.

Resumen

Los meningiomas surgen de la cubierta meníngea del sistema nervioso central. Los meningiomas pediátricos son tumores infrecuentes que representan del 0,5% al 5% de los tumores del sistema nervioso central en edad pediátrica, siendo el tumor cerebral primario no glial más común. No hay evidencia confirmada de la patogenia de los meningiomas pediátricos. Por lo general, se localizan en la convexidad supra o infratentorial, intraventriculares y en la base del cráneo. La presentación clínica de los meningiomas pediátricos es poco específica y varía según su ubicación y tamaño. Los subtipos de meningiomas en la infancia son principalmente meningoteliales grado I de la OMS (32%). El tratamiento de elección es la resección completa del tumor (Simpson I) para prevenir la recurrencia y mejorar el pronóstico. Presentamos el caso de una niña de 9 años con un gran meningioma frontal, el informe de prevalencia en nuestra institución y una revisión de la literatura actual de esta patología.

Palabras clave: Meningioma pediátrico, revisión, epidemiología.

Introduction

Meningiomas arise from the meningeal coverings of the central nervous system. Pediatric meningiomas are infre-

quent tumors accounting for 0.5% to 5% of central nervous system (CNS) tumors in the pediatric age group, being the most common nonglial primary brain tumor¹. The management of these

tumors is challenging as they are usually large at presentation². We report a case of a 9-year-old female child with a large frontal meningioma who presented with non-specific symptoms. We

also present a review on pediatric meningiomas based on current evidence.

Case report

History and examination

A 9-year-old female child from a rural area, was referred from an outside facility for a history of a 9-day dull frontal headache that interfered with her daily activities. Her past medical history includes seizures since she was 8 months old, controlled with valproate according to her parents. The patient's antenatal and perinatal period was uneventful, and she had achieved normal developmental milestones. She gave no history of other symptoms. At first, she was examined in a hospital of the area, where a magnetic resonance imaging (MRI) study was performed, observing a neoformative image that occupied a large part of the right frontal lobe. On physical exam the child was conscious, alert, but hypoactive. No focal abnormalities were found on neurological examination. Coronal suture diastasis was palpated.

When MRI was reviewed (Figure 1), it revealed a large lobulated lesion of size 94 x 93 x 88 mm which was hypointense on T1, hyperintense on T2 with peritumoral brain edema, intensely enhancing, that occupied most of the right frontal area and anterior fossa, collapsing the ipsilateral lateral ventricles and displacing the midline. Based on radiology, a differential diagnosis of meningioma was considered. After informed consent, the patient was taken for surgery.

Surgery and postoperative course

Under neuronavigation assistance, tumor volume and main vessels were established. The patient underwent an extended bifrontal craniotomy for tumor resection. Durotomy was performed, evidencing a highly vascularized tumor of fibrous consistency. The margins of the tumor were dissected, controlling hemostasis, through the parieto-temporal and fronto basal area, to the contralateral frontal region. With the assistance of neuronavigation, vascular structures were identified on the basal aspect and the sylvian valley, which was displaced to the posterior part. The right middle cerebral artery was protected until achieve devascularization of the tumor and advance with the dissection to the point of implantation in

the fronto basal region. After 14 hours of surgery, Simpson grade 1 tumor resection was achieved, dural closure required the use of a dura mater substitute, and a subgaleal drain was placed. Intraoperative blood loss was 1,000 ml. The patient passed the immediate postoperative period in the ICU, was extubated and had no neurological deficits in the subsequent six days of hospitalization. The subgaleal drain was removed on the fourth postoperative day. Postoperative noncontrast computed tomography of the head showed no residual tumor (Figure 2).

Histopathological examination

Histopathology report revealed a WHO grade 1 meningothelial meningioma, showing positive staining for Vimentin and EMA, S100 negative. The KI67 index was 10%.

Postoperative follow-up

At her 1-month postoperative visit,

her symptoms had resolved. Follow-up MRI (Figure 3) shows changes in right frontal and parietal bones with leptomeningeal enhancement and fluid collection in the subdural space of possible posoperative origin.

Discussion

Meningiomas are considered slowly growing benign tumors originating from arachnoidal cap cells of the meninges³. Although they are the most common primary intracranial neoplasm in adulthood (20%-30%), they are relatively rare in the pediatric population, constituting 0.5-5% of pediatric central nervous system (CNS) tumors^{4,5,6}. They are twice as common in women as in men whereas in children there is a slight male predominance, and have been shown to behave quietly differently in children, with atypical or malignant meningiomas representing around

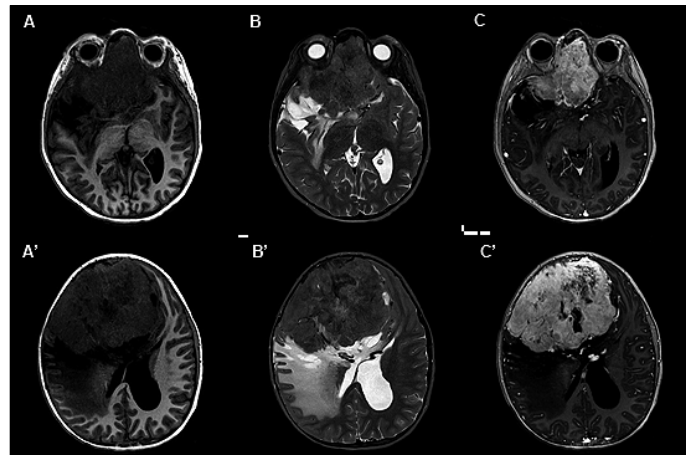


Figure 1. MRI: (A-A') T1W axial; (B-B') T2 axial; (C-C') T1W gadolinium -enhanced axial.

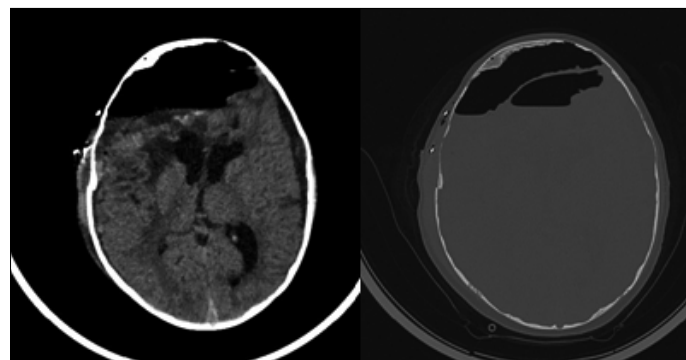


Figure 2. Postoperative noncontrast computed tomography of the head.

20%-25% of cases⁷.

From 2013 to early 2018, our institution reported 64 pathology-confirmed cases of meningiomas, with 8 (12.5%) cases presented in pediatric population. Mean age at diagnosis was 13.5 years. Of them, 50% had tumors located on supratentorial convexity. All patients had tumors classified as WHO grade I: 3 with fibroblastic meningiomas, 1 with transitional, 2 with meningiothelial and 2 with metaplastic. In contrast with Grossbach et al⁷ who reported 12 cases with WHO grade II and III being the most common histological subtype. According to the medical literature, there is no confirmed evidence for the pathogenesis of pediatric meningiomas; but there are many factors that may be associated such as neurofibromatosis (type 1 and type 2) and ionizing radiation^{4,7,8}. However, the latency to meningioma formation after exposure to cranial radiation is quite long and are often atypical or malignant.

In children, meningiomas may develop anywhere in the cranium. Usually they are located in the supra or infratentorial convexity, intraventricular and skull base. When compared with adult meningiomas, the frequency of intraventricular meningioma is very high (12% in children vs 0.5%-4.5% in adults)⁹. The clinical presentation of pediatric meningiomas is nonspecific, varies according to its location and size. The most common symptom is headache and convulsions (25%-35%). On the other hand, in infants, the only presentation may be an increase in head circumference. On physical examination, there isn't characteristic features that

help differentiate meningioma from other cranial neoplasm⁷. Our patient presented a history of seizures since her first year of life, a condition that was not evaluated by a specialist, which could have been the origin of her pathology. Histologically and by frequency, according to Caroli et al⁹, meningiomas subtypes in childhood are mainly meningiothelial (32%), followed by fibrous (25%), transitional (22%), anaplastic (9%), angiomatous (6%), psammomatous (2%), atypical (1.2%), papillary (0.9%), chordoid (0.6%), microcystic (0.3%), clear cell (0.3%) and lymphoplasmacytic (0.3%).

The diagnosis is made by imaging techniques. On MRI, pediatric meningiomas share similar features with their adult counterpart, but one of the main difference is that they tend to lack the "dural tail" or sign of dural attachment in up to 27%¹⁰. Also, meningiomas in childhood are frequently larger at presentation, more than 40% of cases are bigger than 5 cm in diameter⁸. This can be explained by the ability of the child's brain to tolerate a slowly growing mass. The treatment of choice is a complete

tumor resection (Simpson I) when a meningioma is in an accessible location to prevent recurrence and improve prognosis¹¹. Surgical resections of these tumors are considered challenging because of their larger size, unusual location, less blood volume in children and tight adherence of the tumor to nerves and vital vessels. Because of higher recurrence risk, the dural origin/attachment should be completely removed⁴. Adjuvant RT for incompletely resected benign WHO grade I meningiomas also improves local control, but many patients will not recur or will progress slowly after surgery and can avoid the potential morbidity of immediate radiation therapy¹². The role of adjuvant RT varies according to the grade of the tumor and the extent of resection. Post-operative meningioma recurrence is related to the microscopic pattern of the tumor and the adequacy of the surgical removal^{13,14}.

Recibido: 24 de enero de 2019
Aceptado: 02 de marzo de 2019

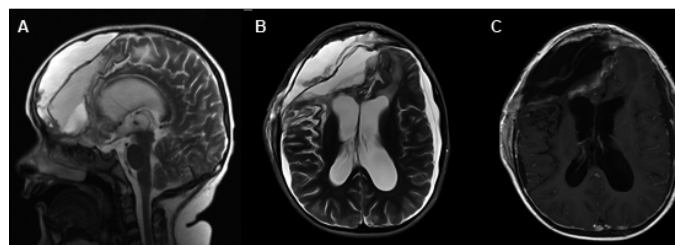


Figure 3. Follow-up postoperative MRI: (A) T2 sagittal; (B) T2 axial; (C) T1W gadolinium -enhanced axial.

References

1. Munjal S, Vats A, Kumar J, Srivastava A, Mehta VS. Giant pediatric intraventricular meningioma: Case report and review of literature. *J Pediatr Neurosci* 2016;11: 219-222.
2. Dudley R, Torok M, Randall S, Béland B, Handler MH, Mulcahy-Levy JM, et al. Pediatric versus adult meningioma: comparison of epidemiology, treatments, and outcomes using the Surveillance, Epidemiology, and End Results database. *J Neurooncol*. 2018;137: 621-629.
3. Rami Almefty. Extrinsic tumors. In: Winn, H Richard (ed.) *Youmans and Winn neurological surgery*. Philadelphia: Elsevier; 2017. p. 2281-2306.
4. Fan M, Fang W, Liu K, Wang C, Deng W, Sun P, et al. Paediatric intracranial meningiomas: eight-year experience with 32 cases. *Chinese Neurosurgical Journal* 2017; 3: 21.
5. Gump W. Meningiomas of the Pediatric Skull Base: A Review. *J Neurol Surg B Skull Base* 2015; 76: 66-73.
6. Kotecha RS, Junckerstorff RC, Lee S, Cole C, Gottardo N. Pediatric meningioma: current approaches and future direction. *J Neurooncol* 2011; 104: 1.
7. Grossbach A, Mahaney K, Menezes A. Pediatric meningiomas: 65-year experience at a single Institution. *J Neurosurg Pediatr* 2017; 20: 42-50.
8. Liu YG, Li F, Zhu SG, Liu M, Wu C. Clinical features and treatment of meningioma in children: report of 12 cases and literature review. *Pediatr Neurosurg* 2008; 44: 112-7.

9. Caroli E, Russillo M, Ferrante L. Intracranial meningiomas in children: report of 27 new cases and critical analysis of 440 cases reported in the literature. *J Child Neurol* 2006; 21: 31-44.
10. Al-Habib A, Rutka JT. (2009) Pediatric Meningiomas. In: Lee J.H. (eds) *Meningiomas*. Springer, London. https://doi.org/10.1007/978-1-84628-784-8_58
11. Aizer AA, Bi WL, Kandola MS, Lee EQ, Nayak L, Rinne ML, et al. Extent of resection and overall survival for patients with atypical and malignant meningioma. *Cancer* 2015; 121:4376-81.
12. Rogers L, Barani I, Chamberlain M, Kaley TJ, McDermott M, Raizer J, et al. Meningiomas: knowledge base, treatment outcomes, and uncertainties. A RANO review. *J Neurosurg* 2015; 122: 4-23.
13. Kim D, Niemierko A, Hwang WL, Stemmer-Rachamimov AO, Curry WT, Barker FG, et al. Histopathological prognostic factors of recurrence following definitive therapy for atypical and malignant meningiomas. *J Neurosurg* 2018; 128: 1123-1132.
14. Li H, Zhao M, Wang S, Cao Y, Zhao J. Prediction of pediatric meningioma recurrence by preoperative MRI assessment. *Neurosurg Rev* 2016; 39: 663.

Correspondence:

Xavier Wong Achi

National Oncologic Institute "Dr. Juan Tanca Marengo" ION-SOLCA, Guayaquil 090514, Ecuador.

xawong@uees.edu.ec